

COMPARISON OF THE CONDITION OF THE PERI-IMPLANT ORAL MUCOUS ACCORDING TO THE RESULTS OF DIGITAL MICROSCOPY

Dmytro Korol¹, Artem Yefimenko², Mykhailo Korol³

¹Department of Orthopaedic Prosthodontics, Ukrainian Medical Stomatological Academy, Poltava, Ukraine
ORCID: <http://orcid.org/0000-0002-8331-0500>

²Company "Vitadent", Zaporyzhzhia, Ukraine
Department of Orthopaedic Prosthodontics, Ukrainian Medical Stomatological Academy, Poltava, Ukraine
ORCID: <http://orcid.org/0000-0002-3088-4981>

³Department of Postgraduate Education of Restorative General Practitioners, Ukrainian Medical Stomatological Academy, Poltava, Ukraine
ORCID: <http://orcid.org/0000-0003-4862-6013>

ARTICLE INFO

Article history:

Received date 19.11.2020

Accepted date 24.12.2020

Published date 30.12.2020

Section:

Practical medicine

DOI

10.21303/2313-8416.2020.001558

KEYWORDS

oral cavity
histogram microscopy
peri-implant mucosa

ABSTRACT

The object of the study there is a level of hyperemia of the mucous membrane around the installed intraosseous dental implants with different coating material according to the results of histogram analysis of digital microscopy.

The problem to be solved – evaluation of the degree of hyperemia of the periimplant mucosa around intraosseous dental implants coated with rutile, in comparison with titanium implants of VT-6 alloy after prosthetics.

Main scientific results: Analysis of digital images using histogram evaluation of the red component of the spectrum showed that 1 month after prosthetics in group 1, which included 20 patients who had intraosseous implants made of titanium alloy TiV6Al (VT-6), the above indicator increased to 191 (St.Err. 4.45). The difference was 4 conventional units. Similarly, in group 2 (16 people) who had intraosseous zirconium implants, there was an increase in the quantitative rate after prosthetics by 9 conventional units, and its value was 194 conventional units (St.Err. 3.64). Since increasing numerical values and shifting the digital histogram to the right is an objective criterion for reducing the intensity of redness, it can be concluded that there is a reduction of mucosal irritation after orthopedic treatment with a predominance of this process in the group of patients who received intraosseous dental implants coated with rutile.

The area of practical use of research results: Since the authors first studied the reaction of the peri-implant mucosa in contact with various implant materials at the stages of orthopedic treatment, this is the basis for the introduction into general medical practice of intraosseous dental implants made in Ukraine using rutile application technology.

The area of application of an innovative technological product – it is a dental implant practice. The obtained results will allow to use more widely Ukrainian implants of non-demountable construction with a high level of surface preparation, for the purpose of further orthopedic treatment with the use of non-removable metal-ceramic dentures.

© The Author(s) 2020. This is an open access article under the CC BY license <http://creativecommons.org/licenses/by/4.0>.

1. Introduction

1. 1. Object of the study

The level of hyperemia of the mucous membrane around the installed intraosseous dental implants of non-demountable construction of domestic production with different coating material.

1. 2. Problem formulation

Partial or complete loss of teeth remains one of the main problems of modern dentistry. Data from the literature on the analysis of the need to restore lost teeth, show a significant prevalence of this problem [1]. In this case, fixed dentures are the most common type of orthopedic structures that have proven their high clinical effectiveness [2, 3].

Orthopedic rehabilitation of patients with dental implants is now a common method of eliminating dentition defects [4]. Dentures based on implants restore aesthetic and masticatory functions, provide patients with a sense of comfort and psychological confidence, do not require the mandatory inclusion of intact teeth in the supporting part. One of the most promising ways to improve this option is to find and implement new materials that would best meet the technological and clinical requirements, especially in the aspect of biocompatibility [5].

Today, scientists are actively looking for options to modify the titanium surface using nanotechnology [6]. An example of such an approach is the creation of an oxidized contact layer (rutile), the study of the properties of which is devoted to a large number of scientific publications [7, 8].

Laboratory studies of the possibilities of rutile in the medical field are in the focus of scientists and researchers in many countries [9].

However, in the domestic scientific literature there is a lack of information on the clinical effectiveness of the use of intraosseous dental implants with rutile-modified surface, and, therefore, the assumption of vasomotor response of periimplant mucosa in contact with rutile surface implant was tested. The comparison group included patients with titanium intraosseous dental implants and fixed non-removable metal-ceramic structures.

The presented results of the research are a fragment of a complex topic of the Department of Propaedeutics of Orthopedic Dentistry of the Ukrainian Medical and Dental Academy (Poltava): "Optimization of prevention and treatment of dental diseases by orthopedic methods" (state registration No. 01020001303).

1. 3. Suggested way to solve the problem

The task of the study was solved using the method of detecting inflammation of the oral mucosa at the stage of orthopedic treatment, which was proposed and protected by the Patent of Ukraine for utility model No. 88400 from 11.03.2014 by Korol D. M. and co-authors [10].

It was assumed that comparing the numerical values of the red color of the histogram spectrum will assess the degree of vasomotor reaction of the periimplant mucosa in contact with rutile, and compare these results with the reaction of the mucosa in contact with the titanium alloy VT-6.

Before the start of the research, two statistical hypotheses were formulated:

- H0 (null hypothesis) – numerical values based on the results of research in the experimental groups will not have statistical differences.
- H1 (alternative hypothesis) – numerical values based on the results of research in the experimental groups will have a statistically significant difference.

2. Materials and methods

The first experimental group included 20 patients who had intraosseous dental implants made of titanium alloy TiV6Al (VT-6). Patients of the second experimental group (18 people) were fitted with titanium implants and rutile-coated products manufactured by Vitadent LTD (Ukraine).

2. 1. Experiments

Examination of the oral mucosa in the peri-implant area was performed using a digital microscope Supereyes B003 with a special conical nozzle. Further computer visualization and processing of the obtained image was performed in Adobe® Photoshop® CS6 extended, which involves the implementation of graphical analysis using tools such as: fragmentation (*Magnetic Lasso Tool*) and "color analysis" (*Color Sampler Tool*).

Changes in the mucous membrane, which would characterize the phenomenon of hyperemia, are recorded on the basis of the intensity of the median of the red spectrum of the image on the color histogram and the numerical values of the average histogram.

The study was performed in a dental chair, the device was set to the maximum magnification of the image and the maximum automatic illumination of the study field, which provided the same standard shooting conditions. A standard conical nozzle for examining the external ear canal included in the microscope kit was autoclaved before the study.

Before photographing the area of the mucous membrane was air dried. The microscope was pressed against the mucous membrane in a given area of the oral mucosa so that focusing and uniform illumination would occur. The resulting image was captured and saved in a format that allowed it to be processed in Adobe® Photoshop® CS6 extended. Subsequently, computer tools were used to work with the image, such as: Magnetic Lasso Tool – a computer fragmentation tool that allows you to select a fragment of the image that needs to be studied, and Color Sampler Tool – color analysis tool allows you to get a color histogram of selected fragment. The degree of hyperemia of the mucous membrane was determined from the intensity of the red spectrum of the image on the color histogram. Decreasing the numerical values of the median of the red component and shifting the histogram to the left corresponds to a greater saturation of the red color.

Thus, from a diagnostic point of view, the fundamentally important indicators of the histogram are the average value of the median red spectrum of the image, because the dominance of red (hyperemia) indicates the process of vasomotor response to stimuli.

Statistical processing of the obtained data and their visualization was performed using the software package Statistica 10.0.

3. Research results

The following results were obtained comparing the effect of the rutile surface in comparison with the surface of the titanium alloy (VT-6) on the condition of the periimplant mucosa. Histogram analysis of microscopic specimens in group 1 patients showed that the median value of the red color was 189 (St.Err. 3.56). The interquartile range of values was between 179 and 197. (**Fig. 1**).

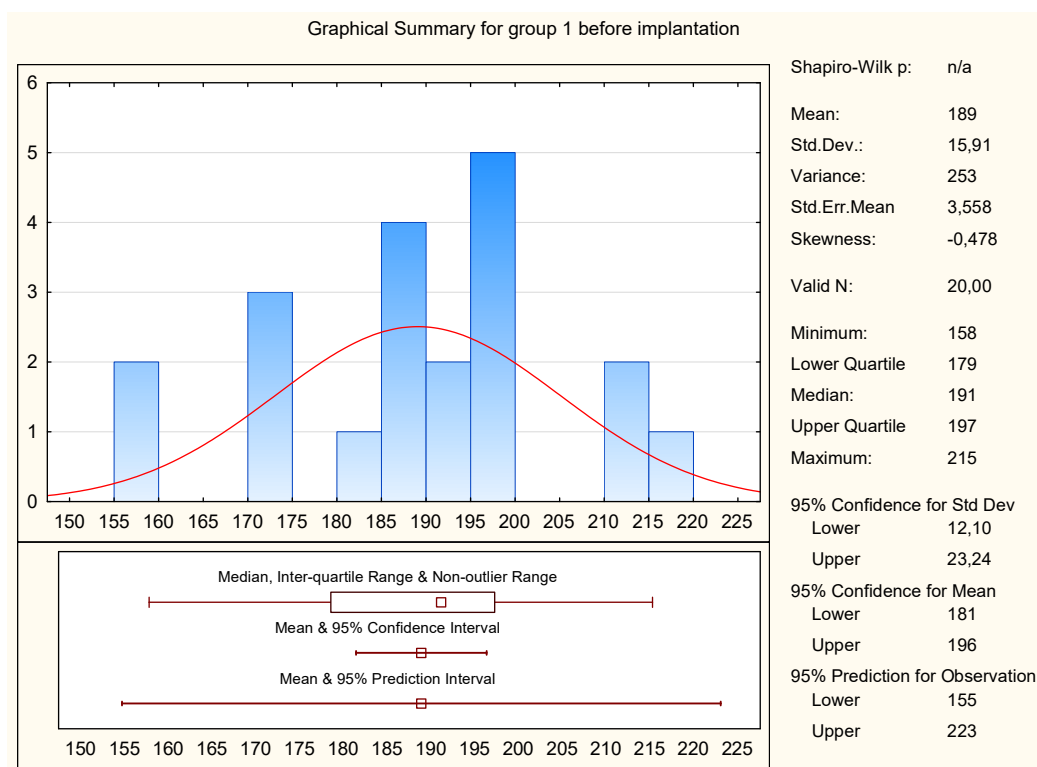


Fig. 1. Diagram of descriptive statistical analysis of the results of microscopy before implantation (group 1)

At the same stage, the mean median value in group 2 patients was 185 (St.Err. 3.94). In the lower quartile this figure was 172, and in the upper – 196 (**Fig. 2**).

After prosthetics, the mean value of the median red in patients of group 1 changed to the level of 191 (St.Err. 4.45) in the interquartile range between 173 and 208 (**Fig. 3**).

In the second group, the mean median red was 194 (St.Err. 3.64) with a minimum and a maximum of 180 and 206, respectively (**Fig. 4**).

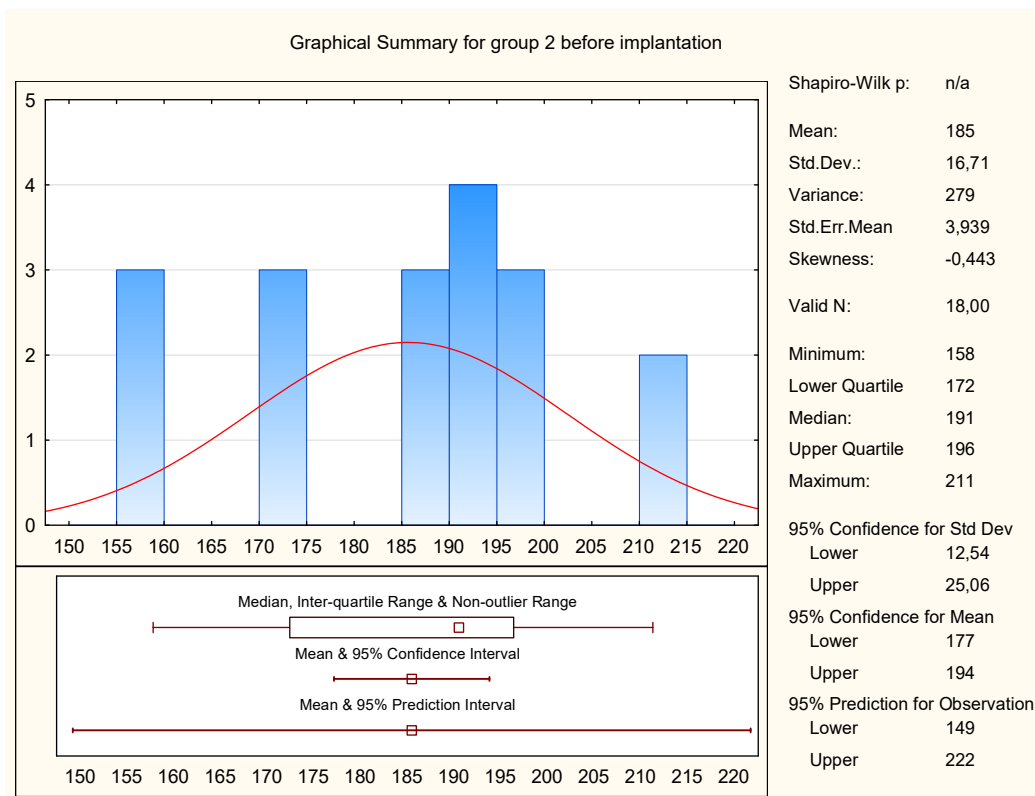


Fig. 2. Diagram of descriptive statistical analysis of the results of microscopy before implantation (group 2)

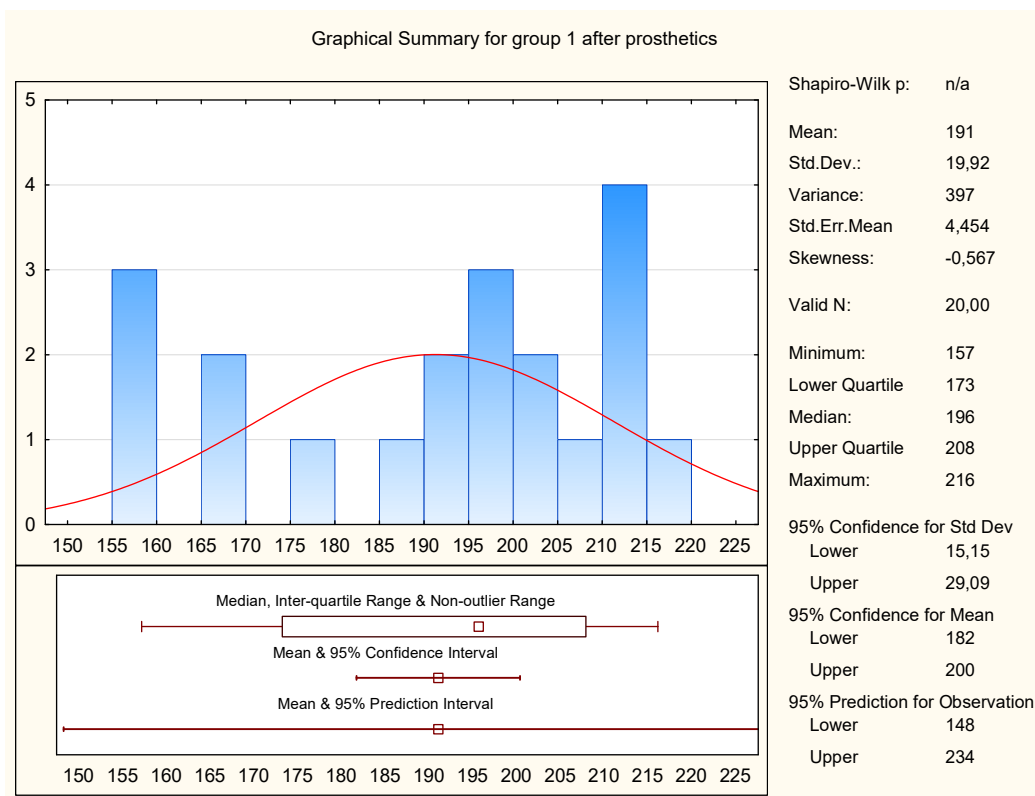


Fig. 3. Diagram of descriptive statistical analysis of the results of microscopy after prosthetics (group 1)

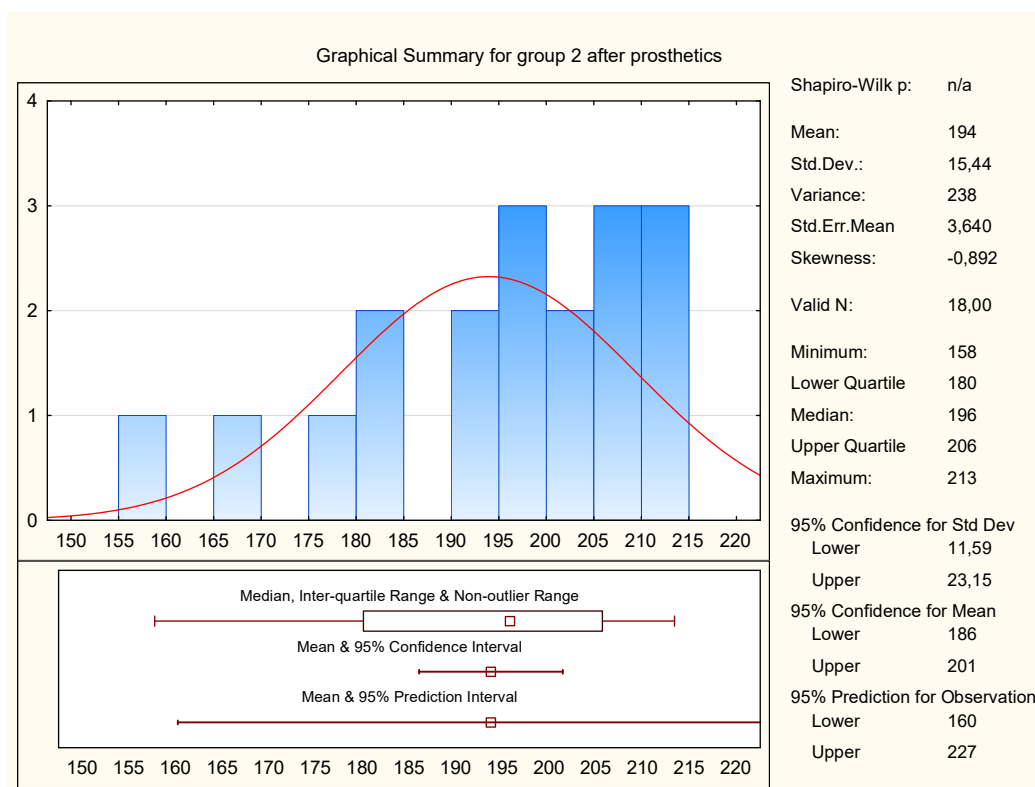


Fig. 4. Diagram of descriptive statistical analysis of the results of microscopy after prosthetics (group 2)

4. Discussions of the research results

Unfortunately, we did not find information on the clinical efficacy of the use of intraosseous dental implants with a rutile-modified surface. Therefore, the hypothesis about the possible vasomotor reaction of the periimplant mucosa in contact with rutile was tested. The comparison group included patients with titanium intraosseous dental implants and fixed non-removable metal-ceramic structures.

It is noteworthy that the above changes in group 1 ($p=0.6$) and in group 2 ($p=0.27$) according to Wilcoxon are not significant, because the null hypothesis of random differences was not rejected.

Further comparison of the results in the intergroup comparison by the Mann-Whitney test showed a relative statistical similarity of the situation, as $p=0.55$ (before implantation) and $p=0.8$ (after fixation of the prosthesis) did not allow to talk about a significant difference.

It was found that 1 month after the completion of prosthetics, the quantitative indicators in both groups increased, with a slight predominance in group (191 and 194 conventional units, respectively). Since an increase in the mean value of the histogram indicates a decrease in redness, we can conclude that over time, the irritation of the mucous membrane decreases. This can be explained, firstly – by the course of the regeneration process, and secondly-- by protecting the mucosa from mechanical injury during eating, and thirdly – by the positive effect of the surface of the implanted material. Despite statistically comparable values in group 1 and group 2, in the group of patients with implants with a rutile surface, the intensity of changes was higher.

Study limitations. Given the design of the microscope with a conical nozzle, the study involved obtaining digital microimages of the mucous membrane around the dental implants exclusively in the frontal area of the alveolar process, accessible ergonomically.

Prospects for further research. Prospects for further research are to increase the number of thematic patients and patients, which will create a complete statistical base of histogram values of digital images of the oral mucosa in the presence of various orthopedic structures, including - based on implants.

5. Conclusions

Comparison of the results of the mean value of the median red colour of the histograms of the microscopy showed that the representatives of the two groups showed an increase in quantitative values. In group 1, this increase was 2 conventional units, and in group 2 – 9 conventional units. Bearing in mind that the increase in the indicators and the shift of the digital histogram to the right is an objective criterion for reducing the intensity of hyperemia, it can be concluded that the irritation of the mucous membrane gradually decreases after orthopedic treatment.

The results of histogram analysis indicate a positive effect of rutile on the condition of the peri-implant shell and opens wide prospects for the use of intraosseous dental implants with the above coating in dental practice.

Conflict of interests

The authors declare that they have no conflicts of interest.

References

- [1] Slinko, Y. O., Sokolova, I. I., Udovichenko, N. M. (2019). The Prevalence of Dental Defects in the Adult Population of Kharkiv Region. *Ukrainskij Zhurnal Medicini, Biologii Ta Sportu*, 4 (6), 260–264. doi: <http://doi.org/10.26693/jmbs04.06.260>
- [2] Pjetursson, B. E., Tan, K., Lang, N. P., Bragger, U., Egger, M., Zwahlen, M. (2004). A systematic review of the survival and complication rates of fixed partial dentures (FPDs) after an observation period of at least 5 years. I. Implant-supported FPDs. *Clinical Oral Implants Research*, 15 (6), 625–642. doi: <http://doi.org/10.1111/j.1600-0501.2004.01117.x>
- [3] Riaz, W., Ayesha, A., Aziz, S. (2018). Dental prosthesis; assessment of grades of failures of conventional fixed dental prosthesis based on severity. *The Professional Medical Journal*, 25 (8), 1261–1264. doi: <http://doi.org/10.29309/tpmj/18.4488>
- [4] Brånemark, P. I., Hansson, B. O., Adell, R., Breine, U., Lindström, J., Hallén, O., Ohman, A. (1977). Osseointegrated implants in the treatment of the edentulous jaw. Experience from a 10-year period. *Scandinavian Journal of Plastic and Reconstructive Surgery*, 16, 1–132.
- [5] Osman, R., Swain, M. (2015). A Critical Review of Dental Implant Materials with an Emphasis on Titanium versus Zirconia. *Materials*, 8 (3), 932–958. doi: <http://doi.org/10.3390/ma8030932>
- [6] Ziental, D., Czarzynska-Goslinska, B., Mlynarczyk, D. T., Glowacka-Sobotta, A., Stanisz, B., Goslinski, T., Sobotta, L. (2020). Titanium Dioxide Nanoparticles: Prospects and Applications in Medicine. *Nanomaterials*, 10 (2), 387. doi: <http://doi.org/10.3390/nano10020387>
- [7] Fabian, E., Landsiedel, R., Ma-Hock, L., Wiench, K., Wohlleben, W., van Ravenzwaay, B. (2007). Tissue distribution and toxicity of intravenously administered titanium dioxide nanoparticles in rats. *Archives of Toxicology*, 82 (3), 151–157. doi: <http://doi.org/10.1007/s00204-007-0253-y>
- [8] Madhubala, V., Pugazhendhi, A., Thirunavukarasu, K. (2019). Cytotoxic and immunomodulatory effects of the low concentration of titanium dioxide nanoparticles (TiO₂ NPs) on human cell lines – An in vitro study. *Process Biochemistry*, 86, 186–195. doi: <http://doi.org/10.1016/j.procbio.2019.08.004>
- [9] Kubiak, A., Siwińska-Ciesielczyk, K., Goscińska, J., Dobrowolska, A., Gabała, E., Czaczyk, K., Jesionowski, T. (2019). Hydrothermal-assisted synthesis of highly crystalline titania–copper oxide binary systems with enhanced antibacterial properties. *Materials Science and Engineering: C*, 104, 109839. doi: <http://doi.org/10.1016/j.msec.2019.109839>
- [10] Korol, D. M., Cherevko F. A., Skubii I. V., Onipko Y. L., Yuschenko, P. L., Kozak, R. V. (2014). Pat. No. 88400 UA. MPK: A61V 5/107; G01N 1/28/. Sposib vyivlennia zapalennia slizovoi obolonky porozhnyny rota na etapi ortopedychnogo likuvannia. No. u 2013 12819; declared: 04.11.2013; published: 11.03.2014, Bul. No. 5.